

EFFECT OF MERCURIC CHLORIDE ON HISTOLOGY OF OVARIES OF AFRICAN CATFISH, *CLARIAS GARIEPINUS*

JALILA MASARAT, K. BORANA & NAHILA SUJAAD

Department of Zoology and Applied Aquaculture, Barkatullah University, Bhopal, Madhya Pradesh, India

ABSTRACT

The freshwater cat fish *Clarias gariepinus* at different duration (0.08 mg/l HgCl₂ for 15, 30, 45 and 60 days) of exposure of mercuric chloride observed. The exposure of mercuric chloride in fish *Clarias gariepinus* resulted in marked degenerative changes in the ovary.

KEYWORDS: Exposure, Mercuric Chloride, Toxicity, *Clarias*

INTRODUCTION

Water pollution is generally associated with heavy industrialization and dense population and is generally one of the major ecological problems. The term heavy metal refers to any metallic chemical element that has a relatively high density and is toxic or poisonous at low concentration. Heavy metals are natural components of the Earth's crust. They cannot be degraded or destroyed. These elements are generally released in small amounts into the environment by processes like weathering of rocks, volcanic eruptions etc. and their intake/exposure is necessary in trace amounts for good health. But, presently, there is a steady increase in their concentration in all habitats owing to mining, electroplating, paints, dyes and battery making industries etc.

Mohammad *et al.*, (1994) studied the bioaccumulation of heavy metal (Cu, Hg, Cd, Cr, Pb and Zn) in five commercially important fishes from kidney in red sea coast, they analyzed the heavy metal in tissue of liver, kidney, gut, gills and muscle. The effects of different toxicants on the aquatic fauna, particularly fish have received attention of many investigators (Athikesavan *et al.*, 2006; Gupta and Srivastava, 2006; Tilak *et al.*, 2007 and Ayaz *et al.*, 2007). However histological and biochemical effects of heavy metals on the ovary received little attention (James *et al.*, 2003; Deshmukh and Kulkarni, 2005). Vinodhini and Narayanam (2008) studied the bioaccumulation of heavy metals in organs of fresh water fish *Cyprinus carpio* (common carp).

MATERIALS AND METHODS

The fish, *Clarias gariepinus*, with average length of 12-15 cm and weight of 100g were procured from local fish markets of Bhopal, M.P, India. The fishes were brought to laboratory and were acclimatized to laboratory conditions for two weeks prior to exposure to mercuric chloride. After the acclimatization period, the fish were randomly selected and stocked at the rate of 20 fish per aquarium in 2 glass aquaria for the experimental runs. The LC₅₀ was determined following the procedure of Finney (1971). The median lethal concentration (LC₅₀) values and their 95% confidence limits for different exposure time were calculated by using the computer software "Probit Analysis", EPA version 1.5, USA. The LC₅₀ value came out to be 0.8 mg/l.

The experiment was set for 60 days in aquaria of 200 L capacity. The fishes were divided into two groups. Group first was kept as unexposed control; IInd Group was exposed to sub lethal concentrations of 0.08 mg/l mercuric chloride.

To study the histopathological changes induced by mercuric chloride, the fishes were exposed to 0.08 mg/l HgCl_2 for 60 days. Fishes were sacrificed by decapitation after 0, 15, 30, 45 and 60 days. Ovaries were removed for histological studies.

RESULTS AND DISCUSSIONS

The LC50 found out for the heavy metal, when exposed to fish, *Clarias gariepinus* to different concentrations of Mercuric chloride for 96 hours, was 0.8 mg/l (Figure 1).

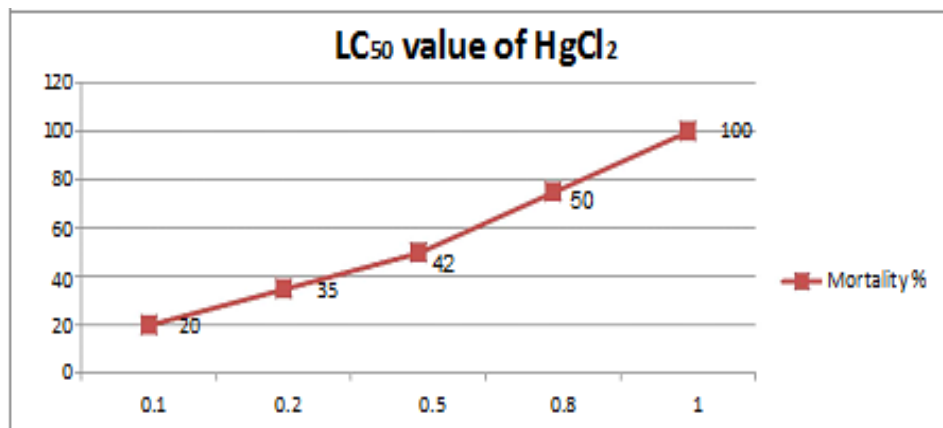


Figure 1: Showing % Mortality with Relation to Different Concentrations of HgCl_2 for 96 Hrs

T.S. of ovary of *Clarias gariepinus* of Group 1 (Control) showed normal histopathological architecture without any pathological lesions in fishes of the control group (Figure 2). After 15 day, the transverse sections of the ovary of the fishes treated with 0.08 mg/l of HgCl_2 revealed damaged follicular lining and deshaped oocytes (Figure 3). After 30 days the ovary of exposed fishes showed severely damaged follicular lining & severely deshaped oocytes (Figure 4). After 45 days the ovary of exposed fishes showed decrease in number and activity of Pre-vitellogenic and vitellogenic oocytes and decrease in the yolk formation (Figure 5). After 60 days the ovary of exposed fishes showed clamping of primary oocytes, damaged and deshaped oocytes and lessening in number of oocytes along with necrosis in some regions of the section (Figure 6).

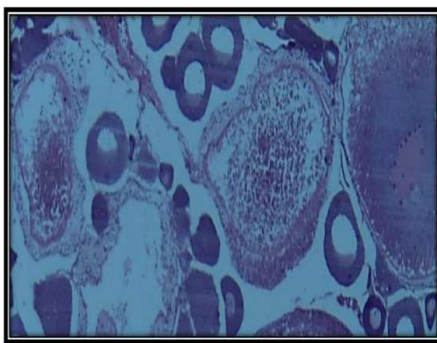


Figure 2: T.S. of Ovary of *Clarias gariepinus* of Group 1 (Control)

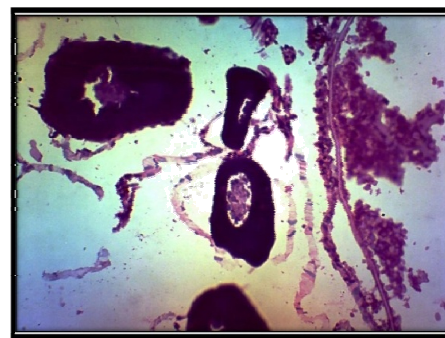


Figure 3: T.S. of Ovary of *Clarias gariepinus* of Group II after 15 Days X 400

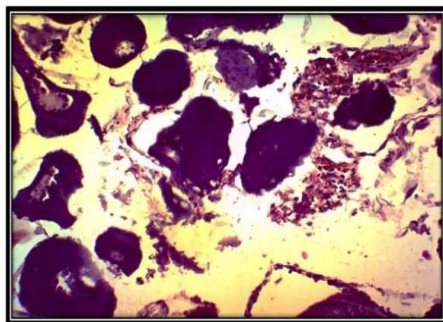


Figure 4: T.S. of Ovary of *Clarias gariepinus* of Group II after 30 Days X 400

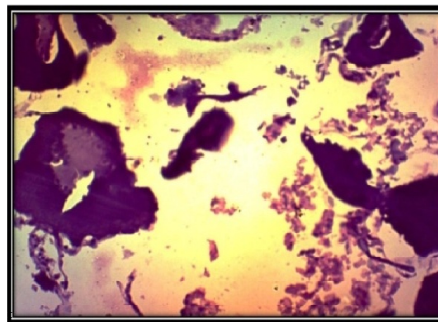


Figure 5: T.S. of Ovary of *Clarias gariepinus* of Group II after 45 Days X400

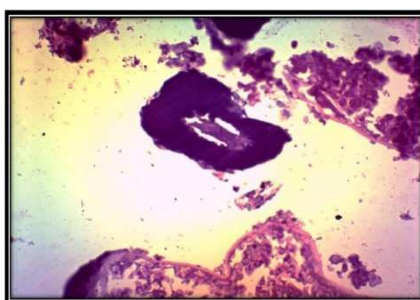


Figure 6: T.S. of Ovary of *Clarias gariepinus* of Group II after 60 Days X 400

In the present study, the exposure of mercuric chloride in fish *Clarias gariepinus* resulted in marked degenerative changes in the ovary. These changes included on 15th day, the transverse sections of the ovary of the fishes treated with 0.08 mg/l of HgCl₂ revealed damaged follicular lining and desheathed oocytes. After 30 days the ovary of exposed fishes showed severely damaged follicular lining & severely desheathed oocytes. After 45 days the ovary of exposed fishes showed decrease in number and activity of Pre-vitellogenic and vitellogenic oocytes and decrease in the yolk formation. After 60 days the ovary of exposed fishes showed clumping of primary oocytes, damaged and desheathed oocytes and lessening in number of oocytes along with necrosis in some regions of the section. Similar to this study, Kumar and Pant (1984) earlier reported a significant atresia in the ovary with major damage to younger oocytes in *Puntius conchoni*, after exposure to zinc on gonads. Das and Baruah (2002) noted partial lysis, swelling, atresia and change in nucleus after exposure for 20 days. Saxena and Garg (1978) also reported that carbaryl treatment arrested ovarian activities and caused increase in atretic follicles in *Channa punctatus*. Chatterjee, Dutta and Ghosh (1997) also studied the impact of carbofuran in the oocyte maturation of catfish, *Clarias gariepinus* and found the degeneration of follicular walls, connective tissue and vacuolization in the ooplasm. In the present study the exposure of mercuric chloride to the fish also causes the degeneration in the ovarian follicles and atresia. According to Shivani *et al.* (2011) ovaries of control fish showed typical histological picture similar to that of a normal fish. Histopathological examination revealed that the fish exposed to 6mg/l of cadmium chloride after 15 days showed enlargement of oocytes and degeneration of egg envelope starts after 30 days. After 45 days atretic follicles appeared, nucleoli got scattered and early and late yolk stages were also observed. According to Guedenon *et al.* (2012) the mortality of *Clarias gariepinus* after 96 hours of exposure to mercury chloride.

CONCLUSIONS

The exposure of mercuric chloride in fish *Clarias gariepinus* resulted in marked degenerative changes in the ovary and found the degeneration of follicular walls, connective tissue and vacuolization in the ooplasm.

REFERENCES

1. Athikesavan, S., Vincent, S., Ambrose, A., and Velmurugan, B. (2006): Nickel induced histopathological changes in the different tissues of freshwater fish, *Hypophthalmichthys molitrix* (Valenciennes). *J. Environ. Biol.*, 27: 391-395.
2. Ayaz, Z, Ekmerkci, G., yerli, S.V., and Ozmen, M. (2007): Heavy metal accumulation in water, sediments and fishes of nallihan bird paradise, Turkey. *J. Environ. Biol.*, 28: 545-549.
3. Chatterjee S., Dutta A.B., and Ghosh (1997): Impact of carbofuron in the oocyte maturation of cat fish, *Heteropneustes fossilis*. *Arch. Environ. Contam. Toxicol* May; 32(4): 426-30.
4. Das and Baruah, B.K., M. (2002): Histopathological changes in ovary of fish *Heteropneustes fossilis* exposed to paper mill effluent. *Aquaculture*, 3, pp 2932.
5. Deshmukh, S.V., and Kulkarni, K. M. (2005): Effect of cadmium chloride on gonads of the fish *Channa orientalis* (Sch.) *Indian J. Environ.*
6. Finney, D.J. (1971):. *Probit analysis*, 3rd Edn., (Cambridge University Press, Cambridge), pp. 20.
7. Guedenon, P., Etorh, A.P., Hounkpatin A.S.Y., Alimba C.G., Ogunkanmi A., Nwokejiege E.G and Boko M.(2012): Acute Toxicity of Mercury (HgCl₂) to African Catfish, *Clarias gariepinus*. *Research Journal of Chemical Sciences* Vol. 2(3): pp 41-45.
8. Gupta, P., and Srivastava, N. (2006): Effects of sublethal concentrations of on histological changes and bioaccumulation of zinc by kidney of fish *Channa punctatus* (Bloch). *J. Environ. Biol.*, 27: 211-215.
9. James, R., Sampath, K., and Edward, D.S. (2003). Copper toxicity on growth and reproductive potential in an ornamental fish, *Xiphophorus helleri*. *Asian Fish. Sci.*, 16: 317-326.
10. Kumar, S., and Pant, S.C. (1984): Comparative effects of the sublethal poisoning of zinc, copper and lead on the gonads of the teleost *Puntius conchonus* ham. *Toxicology Letters*, 23, pp 189-194.
11. Mohammed, M. (1994): Residue of some heavy metals in fishes collected from Red Sea Coast, Jizan, Saudi Arabia. *J. Environ. Biol.* 15(2), 1149-1157.
12. Saxena, S. and Garg, H. (1978):. Effect of insecticidal pollution on ovarian recrudescence in the fresh water teleost *channa punctatus* (Bloch) *Ind. J. Exp. Biol.* 16, 690-691.
13. Shivani Sharma, Susan Manhor, Qureshi. T. A., Pinky Kaur, and Dar. B. A. (2011): Histological Studies on the Cadmium Chloride Exposed Air Breathing Fish, *Heteropneustes fossilis* (Bloch) With Special Reference to Ovaries. *International Journal of Environmental Sciences* Volume 2, No 2, 2011. Pp 411-416.
14. Tilak, K.S., Veeraiah, K., and Milton, P.R.J. (2007): Effects of ammonia, nitrite and nitrate on hemoglobin content and oxygen composition of fresh water fish, *Cyprinus carpio* (Linnaeus). *J. Environ. Biol.*, 28: 45-47.
15. Vinodhini, R. and Narayanan, M.(2008): Heavy Metal Induced Histopathological Alterations in Selected Organs of the *Cyprinus carpio* L.(Common Carp) *Int. J. Environ. Res.*, 3(1):95-100, Winter 2009 ISSN: 1735-6865.